

Lateral Crural Steal and Lateral Crural Overlay

An Objective Evaluation

Hossam M. T. Foda, MD; Russell W. H. Kridel, MD

Objective: To assess objectively the effect of 2 cartilage-modifying techniques, lateral crural steal (LCS) and lateral crural overlay (LCO), on the degree of nasal tip projection and rotation.

Design: A prospective trial using computer imaging techniques for assessment.

Settings: Half of the patients were seen at a university hospital and the other half at a private practice.

Patients: A selected series of 30 patients seeking rhinoplasty mainly for nasal tip repositioning. Only patients with no history of previous nasal operations were included.

Intervention: All patients were operated on using an external rhinoplasty approach. Only 1 of the 2 techniques was adopted for each patient. The technique selected depended purely on clinical judgment.

Main Outcome Measures: The nasofacial angle and the Goode ratio were used to assess tip projection, and the nasolabial angle and rotation angle were used to assess tip rotation.

Results: The use of the LCS technique resulted in an increase in both nasal tip projection and rotation, but the use of the LCO technique resulted in an increase in tip rotation and a decrease in tip projection ($P < .001$). Additionally, the LCO technique resulted in significantly higher degrees of rotation than the LCS technique ($P < .001$).

Conclusions: The LCS procedure is indicated when a moderate increase in nasal tip projection and rotation is desired. The LCO technique is useful in patients where severe underrotation is associated with overprojection.

Arch Otolaryngol Head Neck Surg. 1999;125:1365-1370

SUCCESSFUL surgical control of the nasal tip is considered the most difficult step in any nasal plastic procedure. Repositioning of the nasal tip depends mainly on changing the degree of nasal tip projection or nasal tip rotation, or both.

The nasal tip projection refers to the posterior-anterior extension of the tip from the vertical facial plane. Tip rotation is defined as movement of the tip along a circular arc, with its radius maintained from the facial plane. Many quantitative methods for measuring the nasal tip rotation and projection have been reported¹⁻³ in the literature.

Nasal tip repositioning techniques can be divided into 2 categories: those that modify the existing alar cartilages and those that augment the nasal lobule with grafts or implants. The lateral crural steal (LCS)⁴ and lateral crural overlay (LCO)⁵ are 2 alar cartilage-modifying techniques described for altering the degree of nasal tip projection and rotation.

In the LCS technique, the lateral crura are advanced onto the medial crura, resulting in an increase in the length of the medial crura at the expense of the lateral

crura. With the LCO technique, the lateral crus is shortened by vertically transecting it and overlapping the cut edges. The aim of our study was to analyze prospectively, in an objective manner, the effect that the LCS and LCO have on the degree of nasal tip projection and rotation.

RESULTS

The initial study group comprised 9 men (30%) and 21 women (70%); the mean age was 32.5 years. Twenty-eight patients (93%) returned 6 months after the operation for reevaluation of the degree of nasal tip projection and rotation. Of these 28 patients, 18 were operated on using the LCS technique and 10 using the LCO technique. Further follow-up of 14 patients 2 years later showed no considerable change in the values of tip projection and rotation that were recorded at 6 months' follow-up.

EFFECTS ON NASAL TIP PROJECTION

The use of the LCS technique was associated with a postoperative increase in the degree of nasal tip projection, as evi-

From the Division of Facial Plastic and Reconstructive Surgery, Department of Otolaryngology-Head and Neck Surgery, Alexandria Medical School, Alexandria, Egypt (Dr Foda); the Department of Otolaryngology and Communicative Sciences, Baylor College of Medicine, and the Department of Otolaryngology-Head and Neck Surgery, University of Texas Health Science Center at Houston (Dr Kridel). Dr Kridel is also in private practice in Houston.

PATIENTS AND METHODS

PATIENTS

Thirty patients requesting rhinoplasty with tip repositioning were enrolled in the study. Only patients with no previous nasal surgery were included, and each was operated on using either LCS or LCO as the only tip-modifying technique. The decision as to which technique to use was made according to a preoperative clinical evaluation of the patient's nasal tip deformity.

All patients were subjected to computer-assisted nasal analysis using imaging software (Uniplast Windowriter, version 1.0; United Digital Systems, Winston-Salem, NC) on an IBM-compatible personal computer. The system also included a video camera, graphics tablet, and stylus.

With the patient seated at a fixed distance from the video camera, the profile view of the face was captured with the head in a natural position. The images were then analyzed, starting by identifying the standard reference points¹⁻³ (**Figure 1, A**) needed for evaluating the degree of nasal tip projection and rotation: the glabella, the most anterior portion of the forehead in the midsagittal plane; the nasion, the most posterior point at the root of the nose in the midsagittal plane; the tip, the most anteriorly projecting point of the nose; the columellar point, the most anterior point of the columella; the subnasale, the junction of the columella and the upper lip; the pogonion, the most anterior point of the soft tissue chin; and the alar point, a point on the alar-facial groove where a horizontal line passing through the tip intersects with a vertical line dropped from the nasion. Quantitative evaluation of the degree of nasal tip projection and rotation was then performed using the cephalometric menu of the software, which automatically measures the distance between any 2 points or the angle between any 3 points.

The nasofacial angle (NFaA) and the Goode ratio (GR) were used to evaluate the nasal tip projection. The NFaA was measured at the intercept of the glabella to the pogonion line with the nasion-to-tip line (**Figure 1, D**), and the GR was calculated by dividing the distance from the alar point to the tip by the distance from the nasion to the tip (**Figure 1, C**). The nasal tip rotation was measured using the nasolabial angle (NLA) and the tip rotation angle (RA) (**Figure 1, B**). The NLA was measured at the intercept of the columellar point to the subnasale line with the subnasale to the labrale superius line, and the RA was measured at the intercept of the tip to the columellar point line with a line tangent to the columella.

At a minimum of 6 months after surgery, the patients' images were recaptured by the computer imaging system, and the previously calculated measurements were reevaluated and compared with their preoperative values (**Figure 2, A and B**).

SURGICAL TECHNIQUE

The external rhinoplasty approach was used in all patients because it allows an accurate, unobstructed appraisal of the cartilaginous framework of the tip in its

natural, undistorted position, and it permits precise modification and suture fixation of the alar cartilage complex. This approach also helps to maintain nasal tip support by avoiding the disruption of tip support mechanisms that happens when using endonasal approaches.

Bilateral alar marginal incisions are connected by an inverted-V transcolumellar incision, and the columellar skin flap is elevated off the medial crura. The skin elevation is continued upward over the bony cartilaginous pyramid in the avascular plane just superficial to the perichondrium and periosteum until reaching the nasofrontal angle. Any dorsal adjustments needed are made before modifying the nasal tip cartilages to reduce the risk of inadvertent disruption of the delicate reconstructed alar cartilage complex. To maintain the nasal tip support, the medial crura are secured to each other using 5-0 polydioxanone horizontal mattress sutures. In patients with wide lateral crura, a conservative cephalic trim of the lateral crura is performed, leaving a strong, intact caudal margin of at least 5 mm.

Lateral Crural Steal

The vestibular skin is undermined from the undersurface of the alar cartilage, starting at the junction of the medial and lateral crura (**Figure 3, B**), then proceeding both laterally and medially for about 5 mm to each side to allow free lateral crural mobilization without restriction by the underlying skin attachments. The lateral crus is advanced medially in a curvilinear fashion onto the medial crus and fixed in its new position using 5-0 permanent mattress sutures just below the newly established dome (**Figure 3, C**). Following independent creation and fixation of the right and left domes, additional narrowing and refinement are accomplished using a transdomal mattress suture placed through the entire tip complex.

Lateral Crural Overlay

An incision is planned so as to cross the midportion of the lateral crus on each side (**Figure 4, B**). The cartilage cut extends in a straight line from the cephalic to the caudal crural margins. Before the cartilage cut is made, the vestibular skin is elevated from the undersurface of the lateral crus for about 5 mm on each side of the planned cartilaginous incision. The free proximal and distal ends of the transected lateral crus are then overlapped and fixed with a 5-0 permanent, transcartilaginous, horizontal mattress-type stitch (**Figure 4, C**). For further refinement of the nasal tip, a 5-0 permanent transdomal suture is placed in a horizontal mattress manner to approximate the domes.

After the nasal tip modifications are completed using the LCS or LCO technique, the nasal skin is redraped to its normal anatomic position, and the transcolumellar and marginal incisions are meticulously closed. Careful taping is needed to maintain proper positioning of the reconstructed tip complex, and a metal splint is positioned over the dorsum. The splint is removed after 1 week, and the nose is retaped for another 5 days to help support the tip while new fibrous attachments are being developed between the nasal skin and the underlying nasal framework.

denced by the significant increase in the postoperative values of both the GR and NFaA (**Table 1**). On the other hand, using the LCO technique was associated with a de-

crease in the degree of nasal tip projection, as proved by the significant drop in postoperative values of GR and NFaA (**Table 1**).

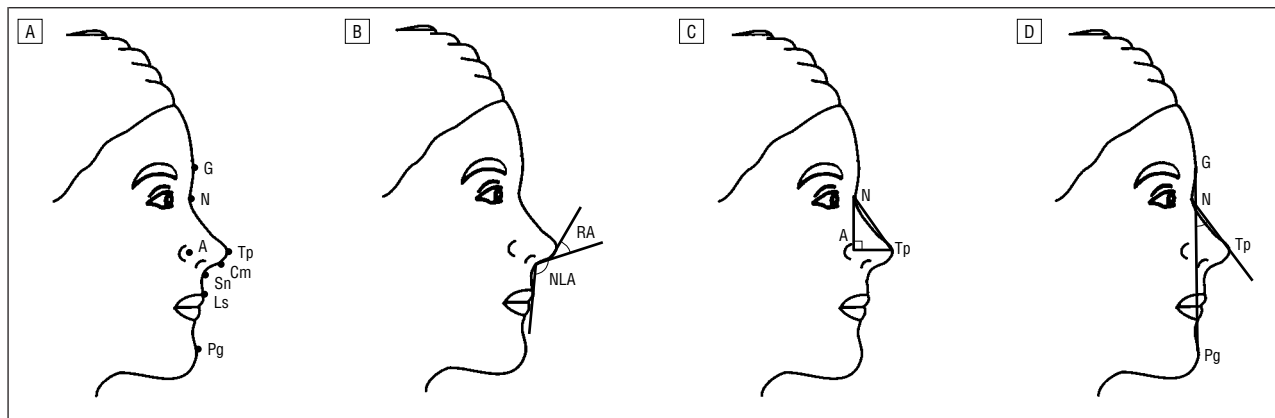


Figure 1. Reference points used for evaluating nasal tip projection and rotation (A) and the methods for measuring (B) the rotation angle (RA) and nasolabial angle (NLA), (C) the Goode method, and (D) the nasofacial angle. G indicates glabella; N, nasion; Tp, tip; Cm, columellar point; Sn, subnasale; Ls, labrale superius; Pg, pogonion; and A, alar point.

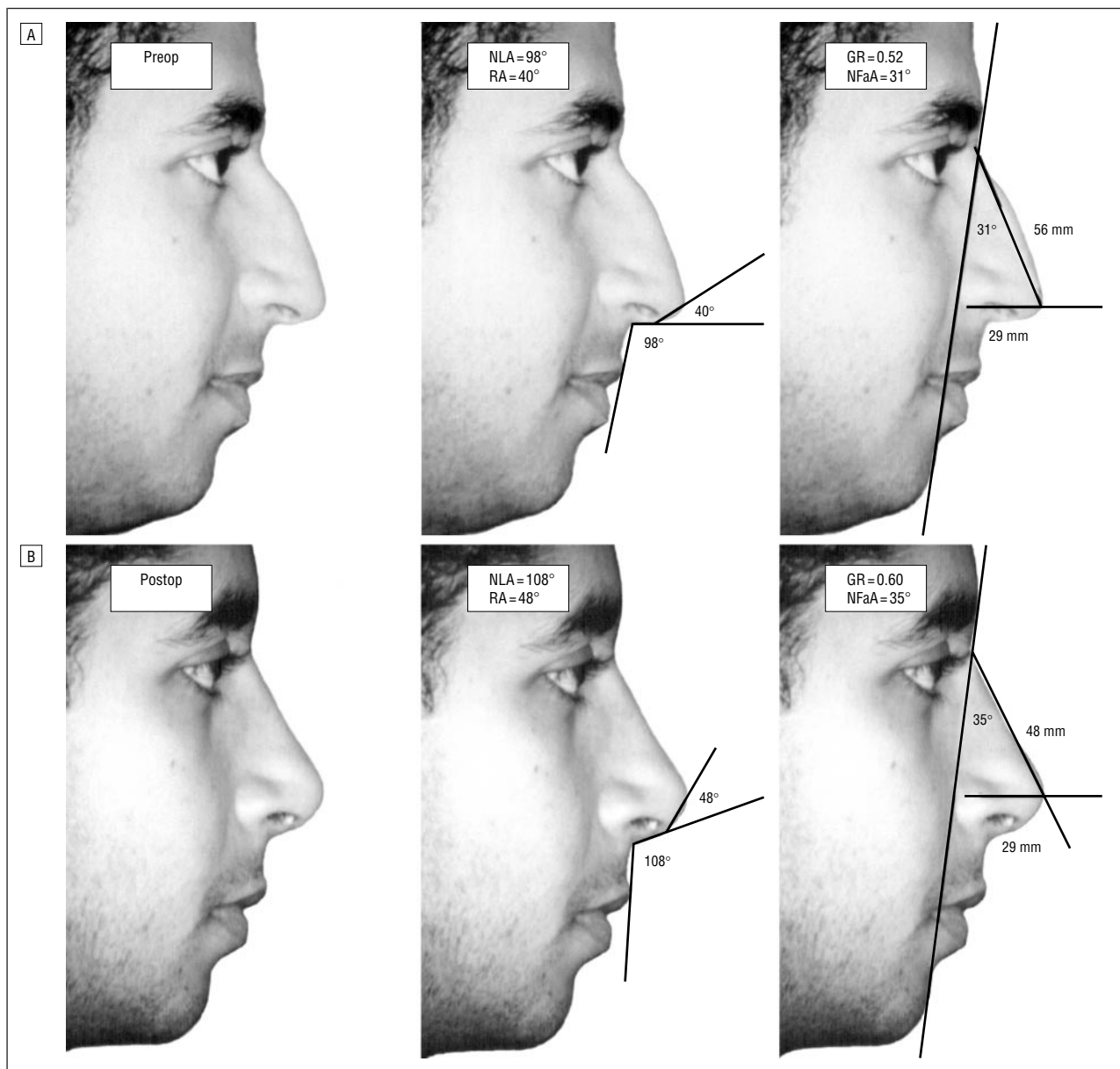


Figure 2. Computer-assisted evaluation of the nasolabial angle (NLA), rotation angle (RA), the Goode ratio (GR), and the nasofacial angle (NFaA) preoperatively (Preop) (A) and postoperatively (Postop) (B).

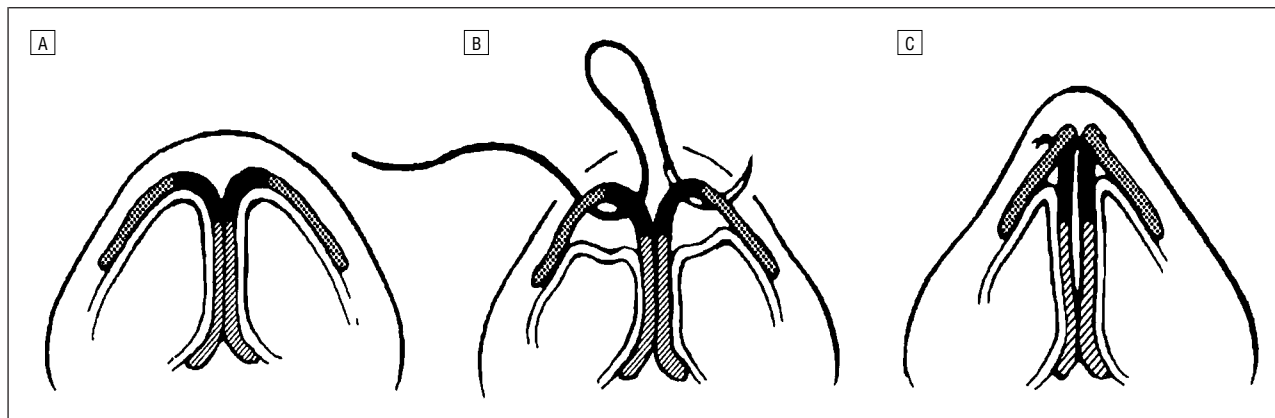


Figure 3. Schematic diagram of the lateral crural steal (LCS) technique: (A) a basal view shows the preoperative anatomy of the alar cartilages, (B) undermining the vestibular skin at the domes and placement of the LCS sutures, and (C) medial advancement of the lateral crura onto the medial crura (reprinted with permission from Kridel et al⁴).

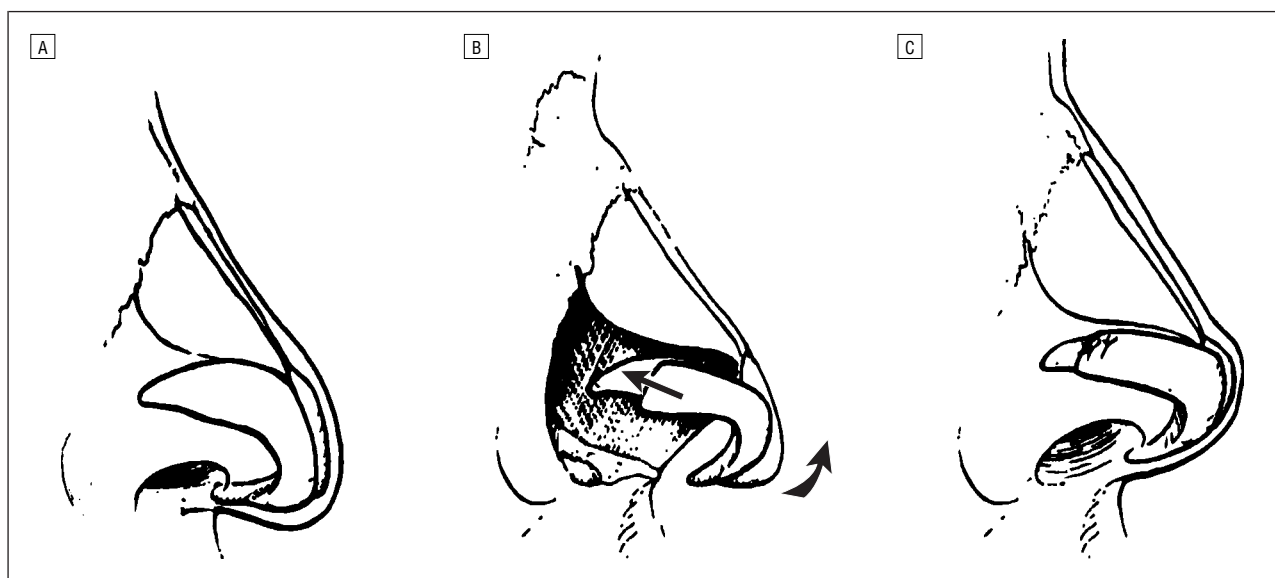

Figure 4. Schematic diagram of the lateral crural overlay technique: (A) the preoperative view, (B) the lateral crus is transected and the free cut ends overlapped, and (C) the overlapped edges are fixed with horizontal mattress sutures (modified from Kridel and Konior⁵).

Table 1. Effects of LCS and LCO Techniques on Nasal Tip Projection*

Technique	GR Difference, Mean (SD)	Paired <i>t</i>	NFaA Difference, Mean (SD)	Paired <i>t</i>
LCS (n = 18)	0.06 (0.03)	8.59†	3.22 (1.52)	9.01†
LCO (n = 10)	-0.05 (0.02)	-9.66†	-3.80 (1.32)	-9.13†

*LCS indicates lateral crural steal; LCO, lateral crural overlay; GR, Goode ratio; and NFaA, nasofacial angle.

†Significant at $P < .001$.

Table 2. Effects of LCS and LCO Techniques on Nasal Tip Rotation*

Technique	NLA Difference, Mean (SD)	Paired <i>t</i>	RA Difference, Mean (SD)	Paired <i>t</i>
LCS (n = 18)	9.67 (6.64)	6.17†	9.77 (1.63)	25.47†
LCO (n = 10)	12.80 (4.47)	9.06†	12.40 (1.35)	29.05†

*LCS indicates lateral crural steal; LCO, lateral crural overlay; NLA, nasolabial angle; and RA, rotation angle.

†Significant at $P < .001$.

EFFECTS ON NASAL TIP ROTATION

The use of the LCS and LCO techniques was associated with an increase in the degree of nasal tip rotation. This increase in the degree of rotation was evidenced by the significant increase in the postoperative values of the NLA and RA (**Table 2**). When the degrees of rotation achieved by using both techniques were compared, the mean increase in the RA using the LCO technique was signifi-

cantly higher than that achieved using the LCS technique ($t = 4.33$).

COMMENT

The successful correction of a nasal tip deformity depends on an accurate assessment of the deformity and the proper selection of the surgical technique to be used. A clear understanding of the effects that each technique has on the dy-

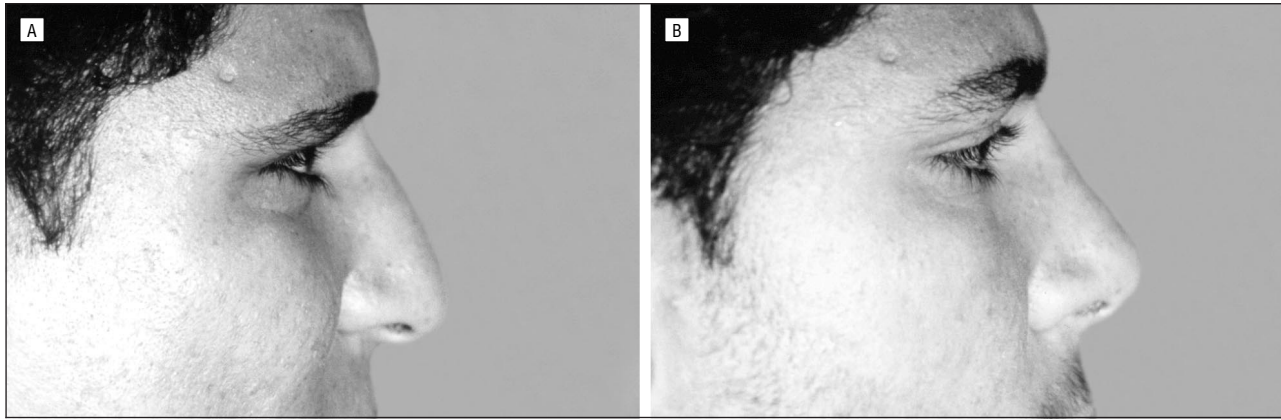


Figure 5. Preoperative view (A) of a patient showing an inadequate degree of tip projection and rotation. The same patient 2 years after the lateral crural steal technique (B) shows maintenance of the gain in projection and rotation.

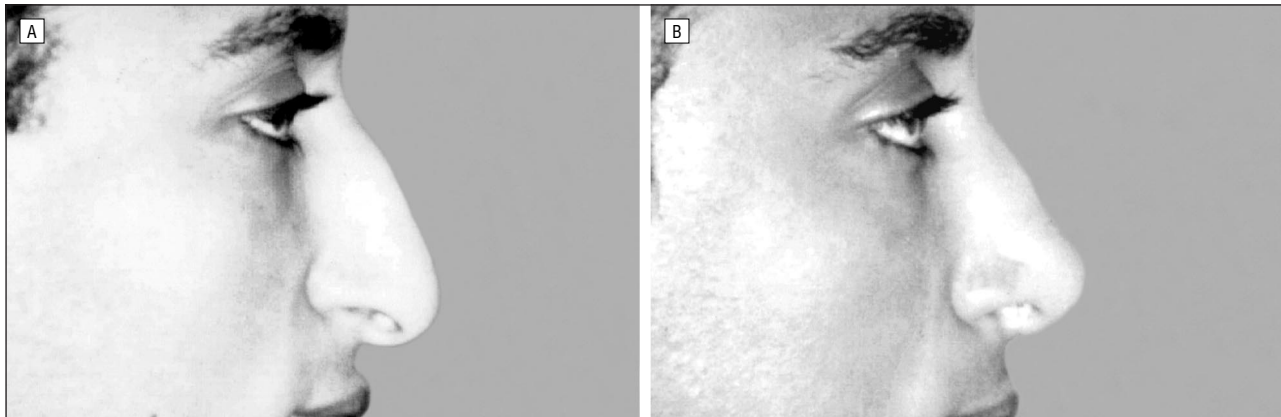


Figure 6. A patient with an overprojected and underrotated nasal tip before (A) and 1 year after (B) being operated on with the lateral crural overlay technique.

namics of the nasal tip is mandatory to be able to select the most appropriate surgical technique to use for each patient.

Despite the large number of publications dealing with nasal tip-modifying techniques, few attempts⁶⁻⁹ have been made to objectively evaluate the effects that any technique has on the position of the nasal tip. Rather, the methods of assessment were always based on subjective judgment by comparing preoperative and postoperative photographs. This was in part because only primitive tools were available to conduct an objective assessment in a standardized reproducible manner. The recent advances in computer graphics technology have made it possible to analyze objectively and accurately the effects of different surgical techniques. In the present study, we used computer imaging to assess, in a quantitative manner, the effect that LCS and LCO techniques have on the degree of nasal tip projection and rotation. To increase the validity of our observations, more than 1 method of measurement was used to assess tip projection and rotation.

The GR and NFA were used to measure nasal tip projection. The GR, which relates the tip projection—measured from the alar point to the tip—to the nasal length, may theoretically increase with any decrease in nasal length. On the contrary, the NFA will increase only if the nasal tip is moved forward, provided that the nasion is not surgically altered, which was the case in all the patients included in this study.

For the measurement of nasal tip rotation, the NLA and the tip RA were used; the NLA is measured at the

subnasale, so it is likely to change with any alteration in the region of the premaxilla and anterior nasal spine. The RA, which is measured at a more anterior point (the columellar point), is changed only by the up-and-down movement of the tip and the infratip lobule.

The relatively small sample size in this study was due to the effort made to include only patients in whom the LCS or LCO was the sole tip-modifying technique used. Patients in whom other techniques were adopted that may have any foreseeable effect on nasal tip projection or rotation were excluded.

Every effort was made to preserve nasal tip support by avoiding maneuvers that interfere with tip support mechanisms, such as lowering the anterior septal angle, severing the interdomal ligament, disrupting medial crural attachments to the caudal septum, and excising caudal septal cartilage or anterior nasal spine.

Anderson,¹⁰ in 1969, introduced the tripod theory in which the cartilaginous framework of the nasal tip simulated a tripod, with 2 upper legs formed by the lateral crura on each side and 1 lower leg formed by the conjoined medial crura. Accordingly, the LCS, which lengthens the medial crura, should move the tip upward and forward, resulting in an increase in the amount of tip projection and rotation (**Figure 5**). On the other hand, the LCO, which shortens the lateral crura, should move the tip backward and upward, leading to an increase in rotation and a decrease in projection (**Figure 6**).

The results of our study conform well with the tripod analogy because the 18 patients who were operated on using the LCS technique had an increase in the GR and NFaA, which reflects an increase in the nasal tip projection. In addition, the degree of nasal tip rotation increased, as evidenced by the increase in postoperative values of the NLA and RA.

The 10 patients who had LCO showed an increase in the degree of rotation and a decrease in projection, as evidenced by the increase in the NLA and RA and the decrease in the GR and NFaA. Finally, the LCO proved helpful in patients with a severely underrotated nasal tip because it resulted in a significantly higher degree of rotation than that achieved by the LCS technique.

CONCLUSIONS

The LCS is more suitable for patients in whom underrotation is associated with poor projection, and the LCO is indicated in patients who have severe underrotation associated with overprojection. A more scientific analysis of the effects that different surgical techniques have in rhinoplasty, demonstrated in the present study, may prove helpful in selecting the most appropriate technique with which to address a nasal tip deformity.

Accepted for publication March 10, 1999.

Presented as a preliminary report at the Fall Meeting of the American Academy of Facial Plastic and Reconstructive Surgery, Washington, DC, September 26, 1996.

Reprints: Hossam M. T. Foda, MD, PO Box 372, Sidi Gaber, Alexandria, Egypt (e-mail: hfoda@dataxprs.com.eg).

REFERENCES

1. Powell N, Humphreys B. *Proportions of the Aesthetic Face*. New York, NY: Thieme-Stratton Inc; 1984.
2. Papell ID. Quantitative facial aesthetic evaluation with computer imaging. *Facial Plast Surg*. 1990;7:35-44.
3. McGraw-Wall B. Facial analysis. In: Bailey BJ, ed. *Head & Neck Surgery—Otolaryngology*. Philadelphia, Pa: JB Lippincott; 1993:2070-2083.
4. Kridel RWH, Konior RJ, Shumrick KA, Wright WK. Advances in nasal tip surgery: the lateral crural steal. *Arch Otolaryngol Head Neck Surg*. 1989;115:1206-1212.
5. Kridel RWH, Konior RJ. Controlled nasal tip rotation via the lateral crural overlay technique. *Arch Otolaryngol Head Neck Surg*. 1991;117:411-415.
6. Hilger PA, Webster RC, Hilger JA, Smith RC. A computer nasal analysis system. *Arch Otolaryngol Head Neck Surg*. 1983;109:653-661.
7. Petroff MA, McCollough EG, Hom D, Anderson JR. Nasal tip projection: quantitative changes following rhinoplasty. *Arch Otolaryngol Head Neck Surg*. 1991;117:783-788.
8. Close LG, Schaefer SD, Schultz BA. The over-projecting nasal tip: precise reduction without rotation. *Laryngoscope*. 1987;97:931-936.
9. Crumley RL, Lanser M. Quantitative analysis of nasal tip projection. *Laryngoscope*. 1988;98:202-208.
10. Anderson JR. The dynamics of rhinoplasty. In: *Proceedings of the 9th International Congress in Otolaryngology*. Amsterdam, the Netherlands: Excerpta Medica; 1969:708-710. Excerpta Medica International Congress Series, No. 206.